

**Innovation in Ophthalmology**

**Novel ointment treatment  
reduces ocular surface  
discomfort and corneal edema  
after cataract surgery**

*Vincenzo Orfeo, Pasquale Napolitano*



# Novel ointment treatment reduces ocular surface discomfort and corneal edema after cataract surgery

Vincenzo Orfeo, Pasquale Napolitano

ISBN 978-88-6756-611-2

ISSN 2035-0252

## Editorial Board

<https://www.springerhealthcare.it/redazione/>

## Production

<https://www.springerhealthcare.it/produzione/>

## WEB address

<https://www.springerhealthcare.it/journal/in-focus/>

## E-mail address

[shcmilan@springer.com](mailto:shcmilan@springer.com)



Via Decembrio, 28  
20137 Milan, Italy

[www.springerhealthcare.it](http://www.springerhealthcare.it)

© 2020 Springer Healthcare Italia S.r.l.

In Focus. Registered in Milan - Registration n. 474 - 7 Aug 1997

Publishing Director: Giuliana Gerardo

Online version

Publication not for resale aimed at medical practitioners.

All rights reserved throughout the world and in all languages. No part of this publication may be reproduced, transmitted or stored in any form or by any means either mechanical or electronic, including photocopying, recording, or through an information storage and retrieval system, without the written permission of Springer Healthcare Italia S.r.l. Springer Healthcare Italia S.r.l. is willing to acknowledge the copyright holder's rights for any image used for which it has been unable to obtain permission to publish.

It should be noted that, although great care has been taken in compiling and checking the content of this publication, Springer Healthcare Italia S.r.l. shall not be held responsible for any use that may be made of this publication or for any errors, omissions or inaccuracies therein.

This publication is not a peer-reviewed publication.

All opinions expressed in this publication reflect those of the authors and not necessarily those of Springer Healthcare Italia S.r.l. or NTC S.r.l.

The possible use of the trade names has the mere purpose of identifying the products and does not imply any suggestion of use.

Each product must be used in accordance with the instructions for use (IFU) and/or summary of product characteristics (SPC) supplied by the relative manufacturing company.

Publication made possible by an unconditioned educational grant from *NTC S.r.l.*

---

# **Novel ointment treatment reduces ocular surface discomfort and corneal edema after cataract surgery**

**Vincenzo Orfeo, Pasquale Napolitano**

*Operative Unit of Ophthalmology, Mediterranean Clinic - Naples*

## **Contents**

|                              |           |
|------------------------------|-----------|
| <b>Abstract</b>              | <b>3</b>  |
| <b>Introduction</b>          | <b>4</b>  |
| <b>Materials and methods</b> | <b>8</b>  |
| <b>Results</b>               | <b>9</b>  |
| <b>Discussion</b>            | <b>11</b> |
| <b>Conclusion</b>            | <b>14</b> |
| <b>Acknowledgments</b>       | <b>14</b> |
| <b>References</b>            | <b>14</b> |



---

# Novel ointment treatment reduces ocular surface discomfort and corneal edema after cataract surgery

**Keywords:** Cataract surgery, Ocular discomfort after cataract, Corneal thickness, Hypertonic saline ointment, Sodium hyaluronate, Hyaluronic acid, Postoperative treatment.

## Abstract

*Cataract surgery is one of the most common surgical procedures performed in Italy and worldwide, with more than 9.5 million cataract surgeries performed throughout the world each year. However, despite the technological improvements, we sometimes observe a delayed recovery due to two specific problems: 1) postsurgical ocular surface discomfort; 2) transient corneal edema (TCE). Patients with these problems report symptoms such as burning, foreign body sensation, dry eye and tearing, which negatively affect their quality of life. Postsurgical ocular surface discomfort may be divided in two different types: 1) immediate discomfort, starting immediately after surgery as a foreign body sensation related to epithelial alteration due to the topical anesthetic; 2) delayed ocular discomfort, starting around 7 days after surgery and persisting for at least 3-4 months. Transient corneal edema is one of the most common complications seen after phacoemulsification. The purpose of the present study was to evaluate the clinical safety and the efficacy of a novel hypertonic ointment (Edenight®) containing 0.4% sodium hyaluronate and 4.5% sodium chloride on the immediate recovery from ocular surface discomfort and transient corneal edema after cataract surgery.*

*We analysed 83 patients who underwent standard cataract surgery, who were divided in two groups: 50 patients in group 1 treated with the hypertonic ointment; 33 patients in group 2 who were not treated with the ointment. We evaluated the level of postoperative ocular surface discomfort with a questionnaire administered 7 days after cataract surgery (5-grade discomfort score). For the analysis of transient corneal edema, we measured the progression of corneal thickness (optical pachymetry) from baseline (before surgery) through the treatment period (day 1 and day 7).*

*The results of this clinical series demonstrate that the use of the hypertonic ointment containing 0.4% sodium hyaluronate and 4.5% sodium chloride immediately after surgery facilitates a rapid decrease of ocular surface discomfort and corneal thickness, improving quality of vision as early as one week after phacoemulsification. In conclusion, the use of Edenight® ointment represents a safe and effective adjunct in postoperative management after cataract surgery.*

## Introduction

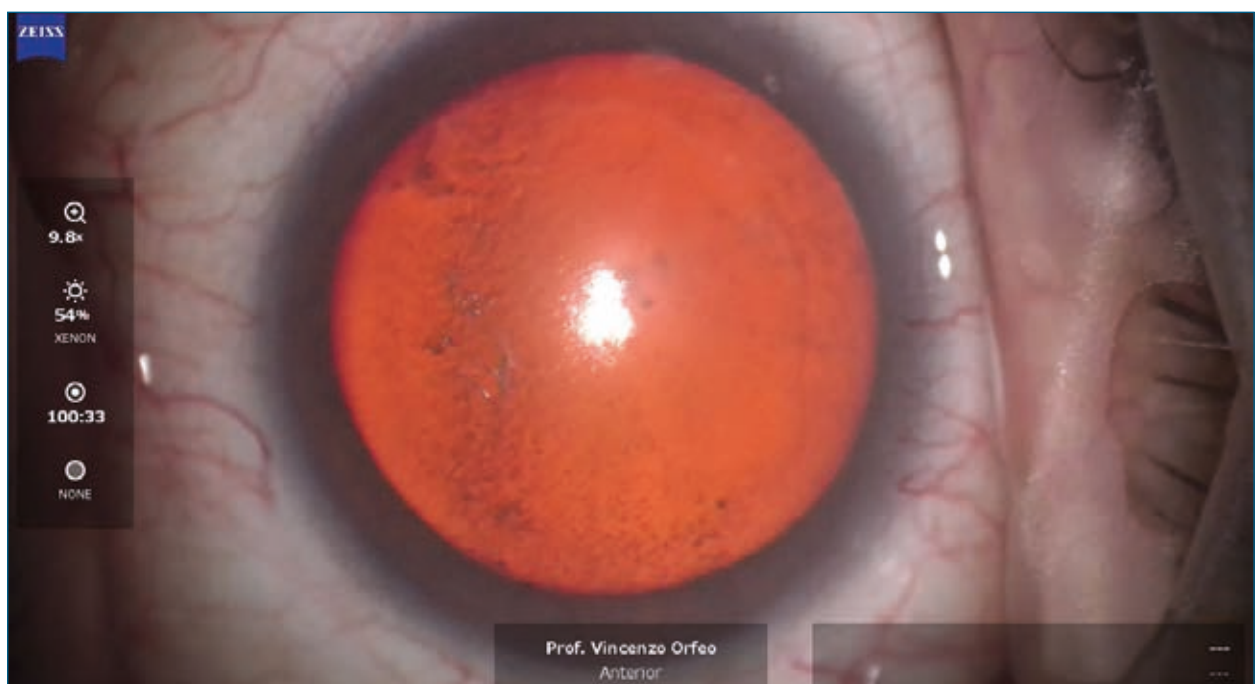Phacoemulsification is the most commonly performed cataract surgery today. With the development of medical science and technology, evolutionary and revolutionary changes have also occurred in cataract surgery, consistent with the shift in the ophthalmology paradigm from rehabilitation of blindness to optimization of vision function.<sup>[1]</sup> Cataract surgery aims to restore optimal vision and is characterized by rapid recovery with minimal side effects, long-term stability, and patient satisfaction.

Sometimes there is a delay in recovery due to two specific problems: 1) postsurgical ocular discomfort; 2) transient corneal edema (TCE). Patients with these problems report symptoms such as burning, foreign body sensation, dry eye, tearing and blurred vision, which affect their quality of life and their quality of sight. In addition, other vi-

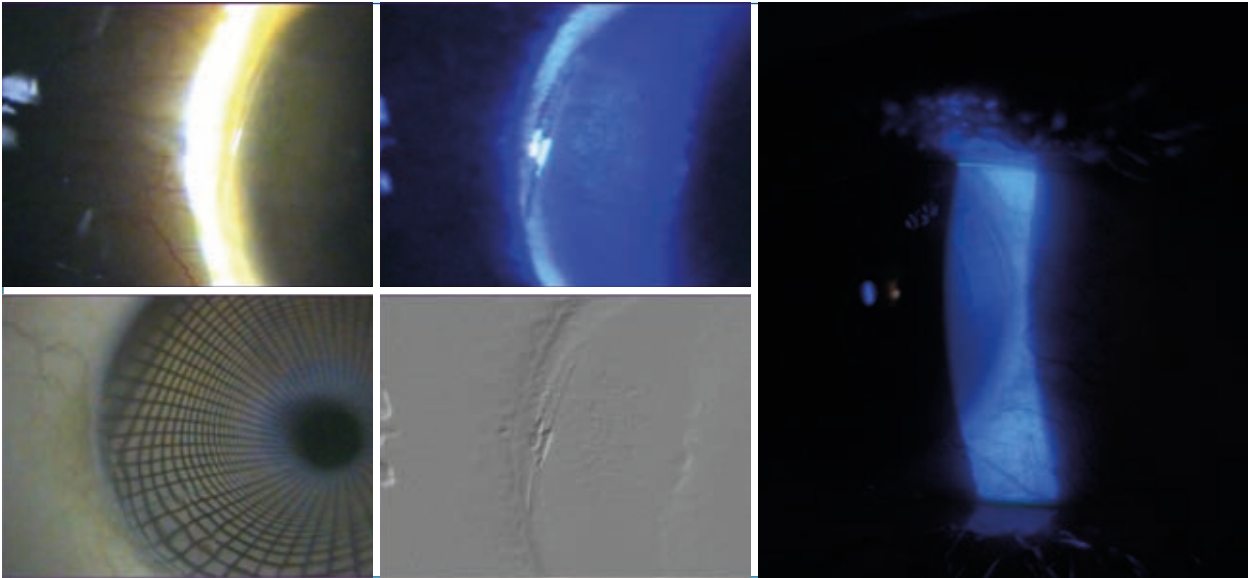
sual disturbances such as blurred vision can be related to a transient postsurgical edema in the first days after the cataract surgery.

Postsurgical ocular surface discomfort can be clinically divided into two different types: 1) immediate discomfort, which begins immediately after cataract surgery; 2) delayed discomfort, starting around 7 days after surgery and persisting for at least 3-4 months.

Immediate discomfort is related to the epithelial alterations caused by preoperative preparation with topical disinfectants and anesthetics, and by irregularity of the corneal incision (**Figure 1**). Furthermore each incision causes a diastasis of the incised flaps,<sup>[3]</sup> which is filled by the epithelial cells. As corneal curvature increases from the periphery to the centre, the further the corneal incisions are advanced towards the centre, the more they induce diastasis.<sup>[4]</sup>



**Figure 1.** Intraoperative picture of an eye with epithelial alteration before cataract surgery. Reproduced from<sup>[2]</sup> with permission of Fabiano Editore.

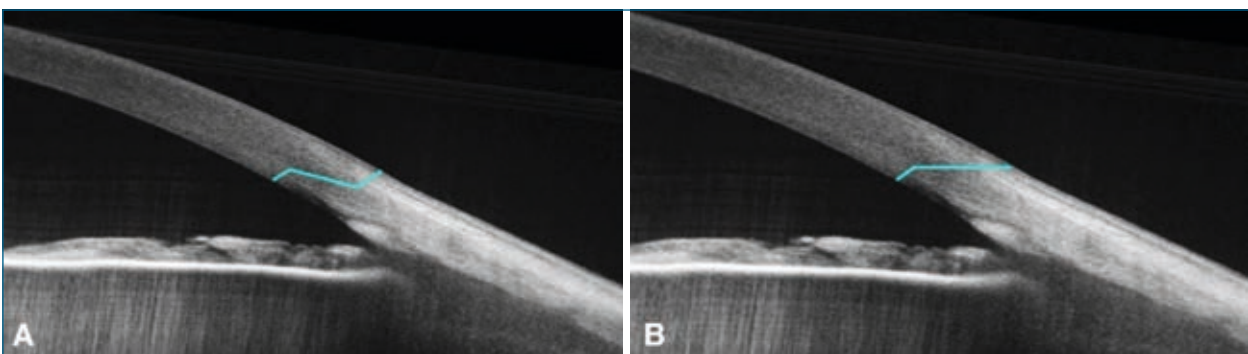


**Figure 2.** Incision diastasis. Reproduced from<sup>[2]</sup> with permission of Fabiano Editore.

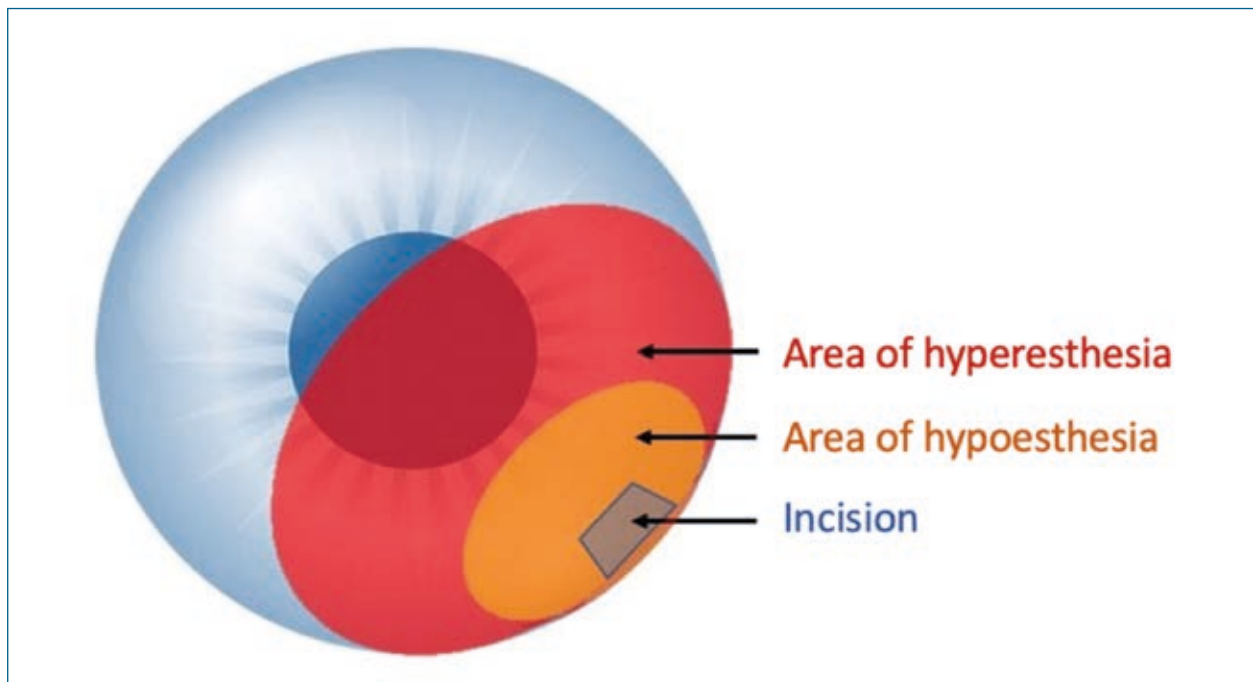
To minimize the diastasis and immediate discomfort, authors suggest making the incision in the corneal periphery just before the conjunctiva. Over the years, several reports have shown a greater diastasis and therefore greater discomfort when the cut is performed in three steps (**Figure 2**), with the first vertical incision. This vertical incision is to be avoided because it tends to cause significant diastasis. A two-step cut, entering the cornea obliquely, significantly reduces possible flap diastasis (**Figure 3**), while providing the same seal.<sup>[2]</sup>

These factors, and in particular the diastasis caused by a three-step cut, are responsible for changes in tear film composition and distribution and resulting areas of surface irregularity with repeated breakage of the tear film in the points of altered epithelium. The final result of these alterations is immediate ocular surface discomfort.<sup>[5]</sup>

Delayed postsurgical ocular surface discomfort is a consequence of corneal nerve cutting. Cutting of the corneal nerve endings plays an important role in delayed discomfort as it results in an area of localized



**Figure 3.** Graphic scheme of a three-step incision (**A**) and two-step incision (**B**). Reproduced from<sup>[2]</sup> with permission of Fabiano Editore.



**Figure 4.** Schematic hypothesis of the alteration of corneal sensitivity surrounding the incision. Reproduced from<sup>[2]</sup> with permission of Fabiano Editore.

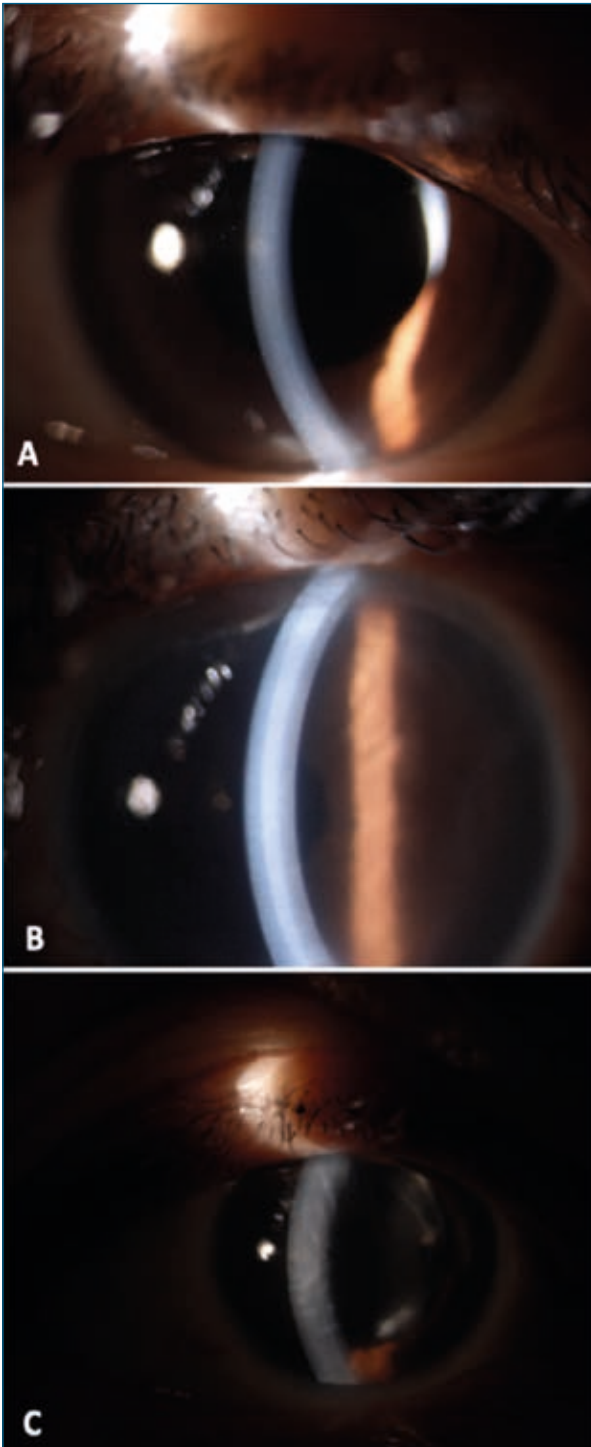
hypoesthesia surrounded by an area of hyperesthesia, which induces hyperalgesia phenomena and a consequent cascade of changes in the efficiency of the nervous regulation of the ocular surface until recovery of the integrity of the nerves (**Figure 4**). These phenomena, starting around 7 days after surgery, may persist up to 3-4 months after cataract surgery.<sup>[6]</sup>

A second aspect of delayed functional recovery can be postsurgical transient corneal edema (TCE).

TCE with faint folds of Descemet's membrane is a relatively common finding after uncomplicated phacoemulsification cataract surgery.<sup>[7]</sup> It is usually detected in the early postoperative period, and resolves spontaneously within a few weeks. Factors contributing to TCE include previous corneal pathology, such as cornea guttata, Fuchs' endothelial dystrophy, age, under-

lying systemic disease, and surgical trauma.<sup>[8]</sup> However, it is not rare to find TCE even in eyes without any detectable risk factors. TCE after phacoemulsification usually regresses within a week after surgery,<sup>[9]</sup> but resolution can be delayed (**Figure 5**). The exact etiology of early postoperative TCE is not clear, but it is probably the result of inflammation or endothelial injury during cataract surgery. Many factors likely affect the corneal endothelium during a phacoemulsification procedure. These can be divided into three groups: (1) direct mechanical trauma to the endothelium due to accidental contact with lens fragments, instruments, or intraocular lenses (IOLs), (2) ultrasound energy affecting the endothelium directly or via the generation of hydroxyl radicals,<sup>[10]</sup> and (3) the effects of the irrigating solution (nature, volume, turbulence). These corneal insults result in tran-





**Figure 5.** Slit-lamp picture of normal cornea (A); moderate corneal edema (B); severe corneal edema (C).

sient postoperative corneal edema caused by a decrease in the endothelial pump function, which occurs to varying degrees early in the course of most cataract proce-

dures, although sometimes subclinically.<sup>[11]</sup> Optical or topical measurements of corneal pachymetry can estimate the severity of the corneal edema.

Given the increasing number of cataract surgeries performed worldwide, postoperative corneal edema, although mainly transient, is a common cause of suboptimal visual outcome.<sup>[12]</sup> To prevent edema development, viscoelastic protective solutions are used during the surgery. The main reason for using viscoelastic solutions, especially sodium hyaluronate (SH), in cataract surgery is to maintain a stable anterior chamber depth and protect the corneal endothelial cells from being damaged during the surgical procedure.<sup>[13]</sup> For this reason it certainly makes sense to reduce corneal edema in the early postoperative period. When the pumping function of the endothelium is impaired, hypertonic solutions, due to their osmotic properties, are able to help restore the state of normal corneal hydration and ensure the elimination of water from the stromal layers throughout the epithelium. As already demonstrated by Knezović et al.<sup>[14]</sup>, hypertonic solutions may have a significant effect on corneal hydration by increasing the transfer of water from the stroma to the tears.

The authors hypothesize that application of a hypertonic ointment containing 0.4% sodium hyaluronate (SH) and 4.5% sodium chloride (NaCl) (Edenight®, NTC S.r.l., Italy) increases saline concentration in the tear film and consequently recalls water from the corneal layers towards the surface. The sodium hyaluronate contained in Edenight® forms a protective shield on

the corneal surface, providing protection and hydration.

The ointment formulation of sodium hyaluronate administered immediately after surgery facilitates application, making it more tolerable to patients and persisting for many hours on the ocular surface. Moreover, Edenight<sup>®</sup>, thanks to its high content of sodium chloride (NaCl), is characterized by a higher osmolarity than the tear fluid: this difference is necessary for reabsorption of the edematous fluid.

## Materials and Methods

A total of 83 eyes in 83 patients (age range, 55 to 82 years) requiring phacoemulsification with IOL implantation were enrolled in this study, performed between June 2020 and September 2020 at the Mediterranean Clinic, Ophthalmology Unit, Naples. All surgical procedures were carried out by the same surgeon, Prof. Vincenzo Orfeo. None of the patients included in the study had a history of dry eye disease, ocular trauma, previous intraocular surgery, planned combined extraction, corneal dystrophies, diabetic retinopathy, uveitis, glaucoma or pseudoexfoliation syndrome, or a proven allergy to one of the hypertonic ointment components. The patients underwent cataract surgery and were divided into two groups: group 1, consisting of 50 patients (23 males and 27 females) treated with 0.4% SH + 4.5% NaCl hypertonic ointment (Edenight<sup>®</sup>, NTC S.r.l., Italy) for 1 week, in addition to the classical postoperative treatment; group 2, consisting of 33

The purpose of the present clinical case series was to evaluate, for the first time, the clinical safety and the efficacy of a 0.4% SH + 4.5% NaCl topical ointment, in addition to usual postoperative therapy (chloramphenicol and betamethasone 4 times daily, indomethacin twice daily and artificial tears three times daily) on pachymetry values in patients with ocular surface discomfort and corneal edema after cataract surgery, compared with usual postoperative treatment alone.

patients (14 males and 19 females) treated with the usual postoperative treatment alone. Edenight<sup>®</sup> was administered by the surgeon immediately after the surgery and then by the patients themselves every night for 7 consecutive days.

The patients' level of ocular discomfort was assessed with a 5-grade discomfort score (grade 1 = no discomfort; grade 2 = low discomfort; grade 3 = medium discomfort; grade 4 = high discomfort; grade 5 = severe discomfort) based on a postoperative questionnaire investigating eye sensation over the days following ocular surgery. The questionnaire, administered to both groups on postoperative day 7, asked the following questions: "Are you experiencing any eye discomfort?", "Have you felt ocular burning, tearing or foreign body sensation?" Patients were instructed to rate their replies on a scale from 0 to 5.

Each patient also underwent slit-lamp examination, fluorescein corneal staining and

tear film BUT measurement (normal values up to 8 seconds), that proved compatible with the score that the patient had assigned to his discomfort.

TCE was evaluated with a Nidek Specular Microscope CEM-530 before surgery, and again one day and one week after surgery. The surgical protocol was standardized in all patients with regard to the administration of topical anesthesia, the type of irrigating fluid (balanced electrolyte solution), Discovisc (1.65% sodium hyaluronate, 4%

chondroitin sulfate; Alcon Italy S.p.A.) and intracameral antibiotic (0.1 ml of preservative-free cefuroxime 0.5%). All surgeries were performed by the same experienced surgeon.

Statistical analyses were performed using the Statplus software package (Version 7.0.1 AnalystSoft, USA). For quantitative values, mean comparisons were performed by a parametric 2-tailed paired Student t-test. A p value of <0.05 was considered statistically significant.

## Results

The patients who received the sodium hyaluronate (SH) 0.4% and sodium chloride (NaCl) 4.5% hypertonic ointment in addition to standard postoperative treatment reported statistically significantly better eye sensation after surgery compared with the group treated with standard therapy alone. As shown in **Table 1**, out of a total of 50 patients in group 1, 25 pa-

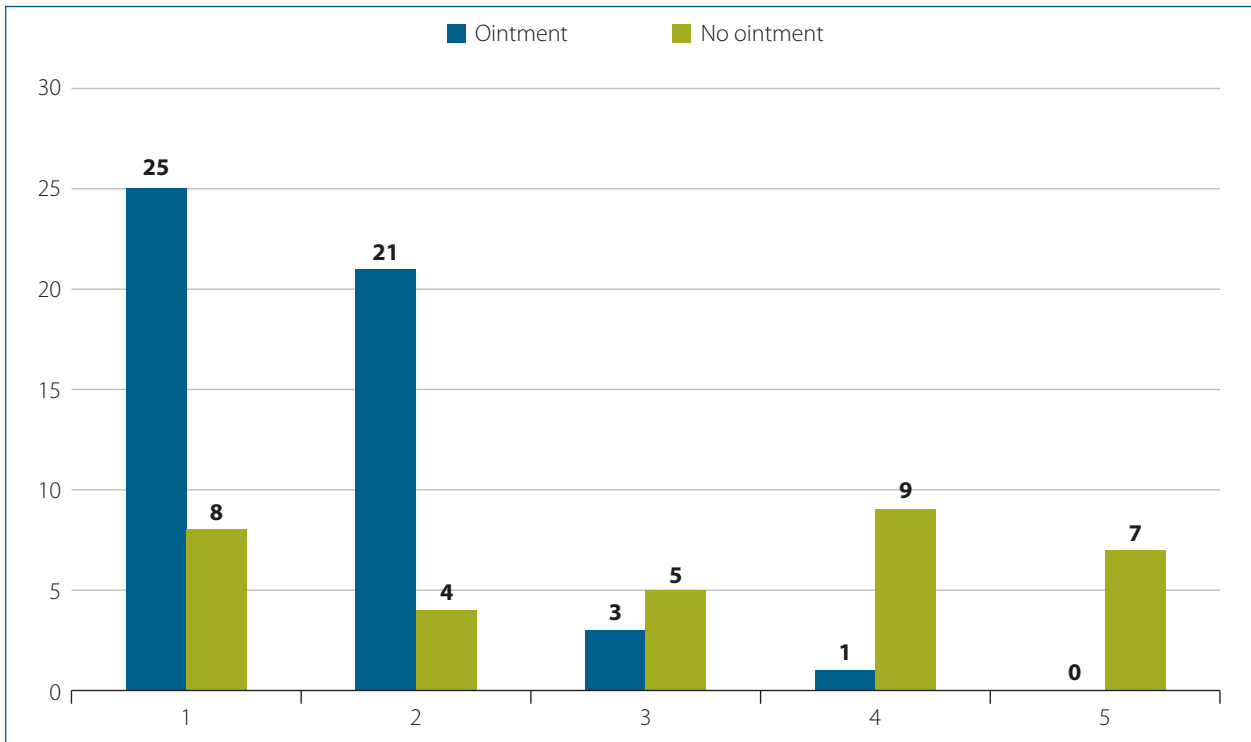
tients (50%) reported no ocular discomfort, 42% (n=21) low discomfort, 6% (n=3) medium discomfort (score of 3), only 1 patient (2%) reported high discomfort, and no patient reported severe discomfort. The postoperative ocular discomfort scores of patients receiving standard postoperative treatment alone are shown in **Table 2**. Out of a total of 33 patients, only 8 pa-

**TABLE 1.** Discomfort score in treated group (Ointment)

| Score | 1   | 2   | 3  | 4  | 5  |
|-------|-----|-----|----|----|----|
|       | 25  | 21  | 3  | 1  | 0  |
|       | 50% | 42% | 6% | 2% | 0% |

**TABLE 2.** Discomfort score in untreated group (No ointment)

| Score | 1   | 2      | 3   | 4      | 5      |
|-------|-----|--------|-----|--------|--------|
|       | 8   | 4      | 5   | 9      | 7      |
|       | 24% | 12.10% | 15% | 27.27% | 21.21% |



**Figure 6.** Discomfort score in the treated group and control group.

tients (24%) reported no symptoms of ocular discomfort, 12.1% (n=4) reported low discomfort, 15% (n=5) medium discomfort (score of 3), 9 patients (27.27%) high discomfort, and 21.21% (n=7) reported severe discomfort.

As highlighted in the graph below (**Figure 6**), we found a significant difference between the group treated with the ointment and the control group, with very low levels of ocular surface discomfort in the immediate postoperative period in the group that used the ointment.

Central corneal thickness increased by an average of 69  $\mu\text{m}$  (+12.8%) (68 in the treated group versus 70 in the controls) on postoperative day 1, showing a significant increase over baseline in both groups.

In the group treated with the Edenight® ointment, central corneal thickness had de-

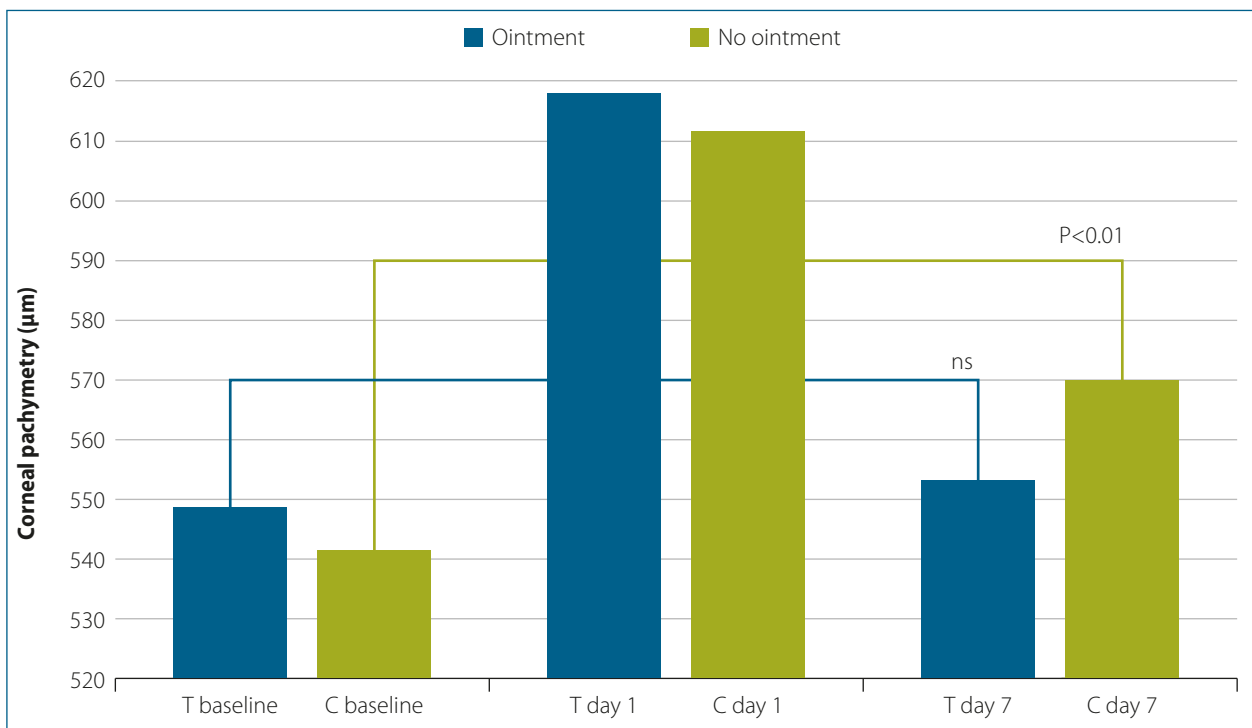
creased by 10% by day 7 after surgery compared with day 1, reverting to preoperative values, and was no longer statistically different from preoperative pachymetry values; in the control group, although central corneal thickness also diminished from day 1 to day 7, it remained nonetheless significantly higher ( $p < 0.001$ ), as shown in **Table 3** and **Figure 7**.

In group 1, mean corneal pachymetry on day 7 was  $554 \pm 43 \mu\text{m}$ , as against a value of  $617 \pm 43 \mu\text{m}$  on day 1, a statistically non-significant difference compared with preoperative pachymetry.

In group 2, mean corneal pachymetry on day 7 was  $570 \pm 43$ , indicating a statistically significant difference from the value at baseline ( $542 \pm 34$ ,  $p < 0.01$ ).

No side effects were observed or reported by the patients in either group.

| Observation period               | Group 1 (Edenight®) | Group 2 (Controls) |
|----------------------------------|---------------------|--------------------|
| Baseline                         | 549 $\pm$ 41        | 542 $\pm$ 34       |
| Day 1                            | 617 $\pm$ 85        | 612 $\pm$ 74       |
| Day 7                            | 554 $\pm$ 43        | 570 $\pm$ 47       |
| Difference day 7 versus day 1    | P < 0.001           | P < 0.001          |
| Difference day 7 versus baseline | ns                  | P < 0.001          |



**Figure 7.** Statistically significant differences in corneal pachymetry ( $\mu\text{m}$ ) in the two patient groups on day 7 versus preoperative values.

## Discussion

The cornea is a vital structure of the eye and some of its critical functions include maintenance of clarity, ocular defense mechanisms, and a powerful converging lens system. The cornea provides two-thirds of the eye's refractive power and

must have smooth surfaces and a high degree of transparency to refract light rays with minimal light scattering. Ocular surface alterations give rise to a variety of symptoms, such as a sensation of foreign body or tearing which may worsen

in the immediate postoperative period.<sup>[15]</sup> Immediate ocular surface discomfort can turn into patient dissatisfaction after cataract surgery regardless of the success of the procedure. As stated, the discomfort could be related to the preoperative patient preparation which alters the normal composition of the tear film causing areas of surface irregularity with repeated tear film break-up.<sup>[16]</sup> In addition, these symptoms could be related to the corneal incision. Each incision induces a diastasis of the incised flaps. This diastasis is filled by the epithelial cells that soften the profile of the incision, smoothing it. However, the more the corneal incision is advanced towards the center of the cornea, the more it causes diastasis and increases the foreign body sensation. Over the following days, cutting of the nerve endings plays an even more important role by inducing an area of localized hypoesthesia, surrounded by an area of hyperesthesia, which leads to hyperalgesia phenomena. Most likely this is at the basis of the discomfort which arises around day 7 and lasts about 3 months. Therefore, in order to explain the discomfort, we have moved from a single, “mechanical” theory to what in most cases may be considered a “neurogenic” theory.<sup>[2]</sup> An additional factor could be “inflamm-aging”, which refers to the inflammatory phenomena or subclinical inflammation present in the elderly that delays the recovery of good functionality.<sup>[17]</sup> A small cut in a clear cornea could sever microscopic nerves of varying size. The elderly patient has a less efficient ocular surface, has less functional recovery and is much more prone to developing in-

flammation caused by damage to the nerve fibers. Furthermore, significant changes in tear film composition have been found after cataract surgery, with a significant presence of cytokines and other inflammatory mediators, such as IFN- $\gamma$ , which promotes the loss of goblet cells on the ocular surface. Inflammatory cytokines could be an important target to be monitored to reduce delayed ocular surface damage following cataract surgery.<sup>[18]</sup> For these reasons, a tear substitute is recommended for at least 3-4 months after surgery. The postoperative course, especially that following the suspension of anti-inflammatory drugs, is often characterized by ocular discomfort due to the presence of a para-inflammatory condition.<sup>[2]</sup>

In this study, the immediate postoperative administration of the hypertonic ointment based on 0.4% sodium hyaluronate and 4.5% sodium chloride (Edenight®) provided excellent results, with a quick restoration of ocular surface homeostasis. This ointment could also be recommended for use a few days before surgery as well as for a longer postoperative period to prevent and treat any symptoms of ocular discomfort.

In addition, when the corneal endothelial cells are injured by a mechanical or chemical insult, they cannot regenerate and fluid accumulates in the cornea, resulting in corneal edema and progressive clouding of vision.

Any appreciable extent of corneal edema is associated with an increase in corneal thickness, reduction in transparency and vision impairment. In recent years, there

has been an increasing interest in the prevention and management of postoperative corneal decompensation, which may lead to transient or permanent visual acuity decrease and patient discomfort.<sup>[19,20]</sup> Osmotic agents are the most frequently used topical medications in physician-based ophthalmology to address the symptoms of corneal edema.<sup>[21]</sup> Several studies have been carried out in order to investigate the efficacy of hypertonic agents in reducing corneal edema. Luxenberg and Green in the 70s demonstrated the effectiveness of topically administered hypertonic agents in seven cases with corneal swelling of varying etiology.<sup>[22]</sup> Other studies documented superior efficacy of 5% sodium chloride ophthalmic ointment (5% NaCl) in comparison to other hyperosmotic agents including colloidal dextran polysaccharide, glycerine, sodium sulfacetamide solution, gum cellulose, and Karo syrup.<sup>[23,24]</sup> Improvement of visual acuity and corneal edema was also demonstrated in patients with bullous keratopathy when treated with the combination of a hydrophilic contact lens and hypertonic saline.<sup>[14]</sup> In 2018 Yin and Levy<sup>[25]</sup> reported favorable results of the use of a hypertonic solution with hyaluronic acid on visual acuity and corneal pachymetry in 45 patients compared with a control group after cataract surgery. The administration of hypertonic formulations usually leads to significant improvement of visual acuity in a short period after phacoemulsification. In the author's experience, the ointment formulation is more effective than the solution form, and the use of a hypertonic ointment at bedtime may improve morn-

ing vision given the minimal evaporation of the tear film overnight.

In this study, we investigated for the first time the safety and efficacy of a hypertonic ointment containing 0.4% sodium hyaluronate with 4.5% sodium chloride (Edenight®) administered postoperatively, compared with standard treatment in patients who underwent uneventful phacoemulsification. We found a better and faster ocular surface recovery in subjects receiving the sodium hyaluronate and hypertonic saline ointment, as assessed by means of the discomfort score. This is most likely related to a better protection of the eye in the immediate postoperative period and downregulation of the production of proinflammatory cytokines after cataract surgery. Sodium hyaluronate, as a viscoelastic polymer, improves stability and restores the balance of the tear film, thereby maintaining the ocular surface lubricated, moisturized and protected. Its viscous nature enables prolonged adhesion to the ocular surface where it exerts its moisturizing and protective action even during the night hours. Moreover, by stabilizing the tear film, it can contribute to visual acuity improvement.

In our study, central corneal thickness recovered significantly faster in subjects receiving the hypertonic saline and sodium hyaluronate ointment, to the extent that the mean thickness measured by pachymetry had returned to preoperative values only one week after surgery. Sodium chloride, thanks to its osmotic power, allows water transfer from stroma to tears, and transiently improves corneal hydration; the hyperosmolar formulation is therefore a logical

and effective treatment for low-to-moderate corneal edema. Sodium hyaluronate has a protective and healing effect on the corneal epithelium and allows better tolerance of the treatment.<sup>[26]</sup>

## Conclusion

The results of our clinical case series show, for the first time, that the postoperative administration of an ointment with the characteristics of Edenight® allows two positive outcomes: 1) on the one hand, a faster restoration of the immediate ocular surface alteration caused by the procedure itself, with improvement of ocular surface and tear film equilibrium and 2) the prevention of corneal edema, which can cause suboptimal vision and last for a long time. Use of the 0.4% sodium hyaluronate with 4.5% hypertonic saline ointment proved to be a simple,

We observed a significant decrease to preoperative findings in pachymetry values at one week post-surgery in patients treated with 4.5% sodium chloride with 0.4% sodium hyaluronate (Edenight®) hypertonic ointment.

safe, well-tolerated and effective adjunct in the management of immediate postoperative ocular surface discomfort and corneal edema after uneventful phacoemulsification, achieving rapid corneal clearance and expediting a good visual outcome, avoiding possible further complications.

Edenight® ointment could also be recommended for use a few days before surgery as well as for a longer postoperative period to prevent and treat the symptoms of discomfort and corneal edema following cataract surgery.

## Acknowledgments

The authors would like to express their very great appreciation to Dr. Simone Calamita, Dr. Emilia Raso and Dr. Rosa Farina orthoptists who work at the Mediterranean Clinical Ophthalmology Unit of Naples, and to Dr.

Alessandro Colombo (NTC) for their valuable and constructive suggestions during the planning and development of this research. Their willingness to give their time so generously has been very much appreciated.

## References

1. Packer M, Fishkind WJ, Fine IH, et al. The physics of phaco: a review. *J Cataract Refract Surg* 2005;31(2):424-31.
2. Orfeo V, D'Andrea L. Il discomfort oculare post chirurgico - Aiccer Educational – Fabiano Editore Italy, 2020.
3. Kasetuwan N, Satitpitakul V, Changul T, Jariyakosol S. Incidence and pattern of dry eye after cataract surgery. *PLoS One* 2013;8(11):e78657.



4. Cho YK, Kim MS. Dry eye after cataract surgery and associated intraoperative risk factors. *Korean J Ophthalmol* 2009;23(2):65-73.
5. Matta S, Park J, Shantha GPS, et al. Cataract surgery visual outcomes and associated risk factors in secondary level eye care centers of L V Prasad Eye Institute, India. *PLoS One* 2016;11(1):e0144853.
6. Marfurt CF, Kruse F, Tervo TMT, Mu LJ. Corneal nerves: structure, contents and function. *Exp Eye Res* 2003;76:521-42.
7. Yi DH, Dana MR. Corneal edema after cataract surgery: incidence and etiology. *Semin Ophthalmol* 2002;17:110-4.
8. O'Neal MR, Polse KA. Decreased endothelial pump function with aging. *Invest Ophthalmol Vis Sci* 1986;27:457-63.
9. Tao A, Chen Z, Shao Y, et al. Phacoemulsification induced transient swelling of corneal Descemet's Endothelium Complex imaged with ultra-high resolution optical coherence tomography. *PLoS One* 2013;8:e80986.
10. Cameron MD, Poyer JF, Aust SD. Identification of free radicals produced during phacoemulsification. *J Cataract Refract Surg* 2001;27:463-70.
11. Behndig A, Lundberg B. Transient corneal edema after phacoemulsification: Comparison of 3 viscoelastic regimens. *J Cataract Refract Surg* 2002;28:1551-6.
12. Rosado-Adames N, Afshari NA. The changing fate of the corneal endothelium in cataract surgery. *Curr Opin Ophthalmol* 2012;23:3-6.
13. Higashide T, Sugiyama K. Use of viscoelastic substance in ophthalmic surgery - focus on sodium hyaluronate. *Clin Ophthalmol* 2008;2:21-30.
14. Knezović I, Dekaris I, Gabrić N, et al. Therapeutic efficacy of 5% NaCl hypertonic solution in patients with bullous keratopathy. *Coll Antropol* 2006;30:405-8.
15. Sutu C, Fukuoka H, Afshari NA. Mechanisms and management of dry eye in cataract surgery patients. *Curr Opin Ophthalmol* 2016;27:24-30.
16. Rolando M, Cantera E, Mencucci R, et al. The correct diagnosis and therapeutic management of tear dysfunction: recommendations of the P.I.C.A.S.S.O. board. *Int Ophthalmol* 2018;38:875-95.
17. Di Zazzo A, Micera A, Coassin M, et al. Inflammaging at ocular surface: clinical and bio-molecular analyses in healthy volunteers. *Investig Ophthalmol Vis Sci* 2019;60:1769-75.
18. Park Y, Hwang HB, Kim HS. Observation of influence of cataract surgery on the ocular surface. *PLoS One* 2016;11:e0152460.
19. Sharma N, Singhal D, Nair SP, et al. Corneal edema after phacoemulsification. *Indian J Ophthalmol* 2017;65:1381-9.
20. Costagliola C, Romano V, Forbice E, et al. Corneal oedema and its medical treatment. *Clin Exp Optom* 2013;96:529-35.
21. Samuel M, Thomasy SM, Calderon AS, et al. Effects of 5% sodium chloride ophthalmic ointment on thickness and morphology of the normal canine cornea. *Vet Ophthalmol* 2019;22:229-37.

22. Luxenberg MN, Green K. Reduction of corneal edema with topical hypertonic agents. *Am J Ophthalmol* 1971;71:847-53.
23. Morris GJ, Winters L, Coulson GE, Clarke KJ. Effect of osmotic stress on the ultrastructure and viability of the yeast *Saccharomyces cerevisiae*. *J Gen Microbiol* 1986;132:2023-34.
24. Green K, Downs S. Reduction of corneal thickness with hypertonic solutions. *Am J Ophthalmol* 1973;75:507-10.
25. Yin GHW, Levy N. Clinical results after 5% sodium chloride treatment in post-operative corneal oedema. *J Eye Dis Disord* 2018;3:1-5.
26. Debbasch, C, De La Salle SB, Brignole F, et al. Cytoprotective effects of hyaluronic acid and carbomer 934P in ocular surface epithelial cells. *Investig Ophthalmol Vis Sci* 2002;43:3409-15.



