

Innovation in Ophthalmology

Corneal edema management with Ededay eye drops in patients who underwent femtolasar cataract surgery: evaluation in the postoperative course

David Ciacci, Francesca Jonsson

Corneal edema management with EdeDay eye drops in patients who underwent femtolasar cataract surgery: evaluation in the postoperative course

David Ciacci, Francesca Jonsson

ISBN 978-88-6756-552-8

ISSN 2035-0252

Editorial Board

<https://www.springerhealthcare.it/redazione/>

Production

<https://www.springerhealthcare.it/produzione/>

WEB address

<https://www.springerhealthcare.it/journal/in-focus/>

E-mail address

shcmilan@springer.com

 Springer Healthcare Communications

Via Decembrio, 28
20137 Milan, Italy

www.springerhealthcare.it

© 2020 Springer Healthcare Italia S.r.l.

In Focus. Registered in Milan - Registration n. 474 - 8/7/1997

Publishing Director: Giuliana Gerardo

Online version

Publication not for resale aimed at medical practitioners.

All rights reserved throughout the world and in all languages. No part of this publication may be reproduced, transmitted or stored in any form or by any means either mechanical or electronic, including photocopying, recording, or through an information storage and retrieval system, without the written permission of Springer Healthcare Italia S.r.l.. Springer Healthcare Italia S.r.l. is willing to acknowledge the copyright holder's rights for any image used for which it has been unable to obtain permission to publish.

It should be noted that, although great care has been taken in compiling and checking the content of this publication, Springer Healthcare Italia S.r.l. shall not be held responsible for any use that may be made of this publication or for any errors, omissions or inaccuracies therein.

This publication is not a peer-reviewed publication.

All opinions expressed in this publication reflect those of the authors and not necessarily those of Springer Healthcare Italia S.r.l. or NTC S.r.l..

The possible use of the trade names has the mere purpose of identifying the products and does not imply any suggestion of use.

Each product must be used in accordance with the instructions for use (IFU) and/or summary of product characteristics (SPC) supplied by the relative manufacturing company.

Publication made possible by an unconditioned educational grant from NTC S.r.l.

Corneal edema management with Ededay eye drops in patients who underwent femtolasers cataract surgery: evaluation in the postoperative course

David Ciacci¹, Francesca Jonsson²

¹ Head of Ophthalmology, Chiros Srl, Turin, Italy;
Director of Ophthalmology Service, Cidimu Group SpA, Turin, Italy;
IRR Rehabilitations Institute, Turin, Italy

² Orthoptist and Ophthalmic Assistant, Chiros Srl, Turin, Italy;
Ophthalmology Service, Cidimu Group SpA, Turin, Italy;
IRR Rehabilitations Institute, Turin, Italy

Contents

Introduction

Objective

Materials and methods

Results

Conclusions

References

2

3

4

4

7

7

Corneal edema management with Ededay eye drops in patients who underwent femtolasar cataract surgery: evaluation in the postoperative course

Introduction

The cornea is a vital structure of the eye that serves a variety of essential functions. Some of the critical functions of the cornea include maintenance of clarity, ocular defence mechanisms, and a powerful converging lens system. The cornea accounts for two-thirds of the eye's power of refraction. It needs to have a smooth surface and a high level of transparency to be able to refract light rays with minimal light scattering. Any mechanical or chemical injury to the cornea that compromises endothelial cell function may lead to corneal edema: injured endothelial cells are unable to regenerate, leading to an accumulation of fluid in the cornea, with consequent corneal swelling and progressive clouding of vision. The formation of corneal edema is a process distinct from that associated with the accumulation of abnormal amounts of tissue fluids in other parts of the body. In fact, the cornea is avascular so that changes in its state of hydration are unrelated to changes in vascular permeability, the usual cause of edema^[1].

Figure 1 and **Figure 2** show examples of corneal edema.

Although corneal edema is due to a diverse group of etiologies, there are basically two pathophysiologic mechanisms that give rise to the condition. Either the 'pump' mechanism of the endothelium is malfunctioning because of primary or secondary endothelial failure, or the 'pump' mechanism is overwhelmed by an increase in intraocular pressure^[2]. In many cases, edema will be secondary to a combination of both factors.

Cataract surgery is a sophisticated procedure assisted by several imaging and diagnostic modalities that facilitate the surgeon's task and lead to a favorable result in the vast majority of cases. Despite technological innovations, many aspects of cataract surgery still remain to be investigated. One of these is predicting the behavior of the corneal endothelium after the load of ultrasonic energy as well as the mechanical manipulations^[3]. Pseudophakic bullous keratopathy (PBK) and aphakic bullous keratopathy (ABK) refer to the development of irreversible corneal edema as a complication of cataract

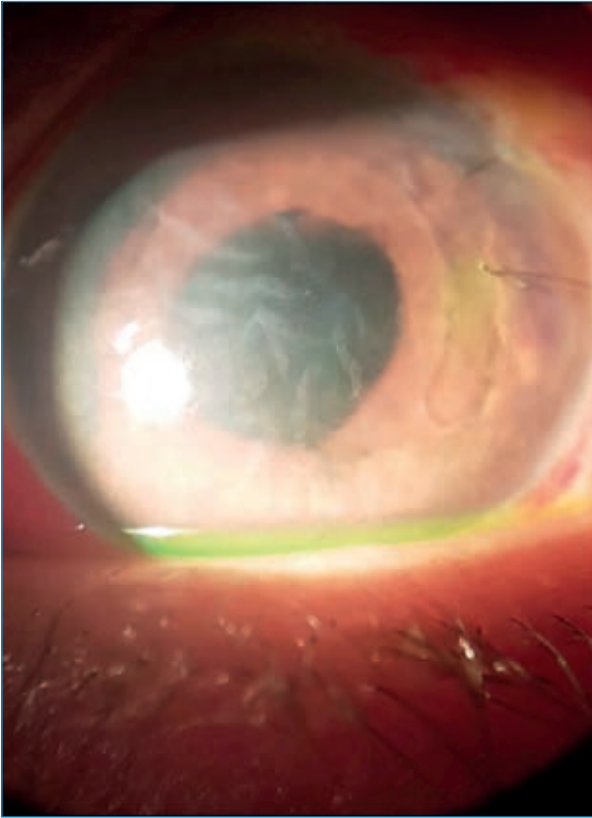


Figure 1. Corneal edema in complicated cataract surgery.

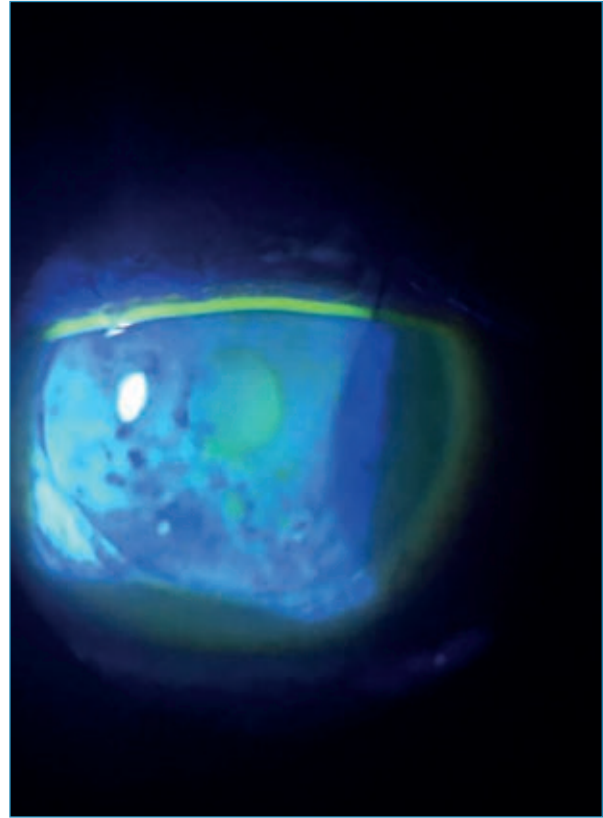


Figure 2. Corneal edema. Fluorescein staining.

surgery^[4]. As corneal edema progresses and worsens, first stromal and then intercellular epithelial edema develops. In summary, corneal edema is a medical condition caused by problems associated with dehydration, endothelial disorder, ocular surgery, viral infections, traumatic

injury, increased ocular pressure, and toxins. Cataract surgery can also damage the endothelial cells, causing corneal edema. Three important treatment goals in corneal edema are reducing discomfort, improving vision and preventing secondary ulceration and infection of the cornea.

Objective

This study aimed at evaluating post-operative edema in cataract-operated patients treated with hypertonic eye drops for 10-12 days postoperatively to accelerate the improvement of vision quality and the reduction of edema.

The study was carried out on 22 patients, of

whom 11 treated with Ededay. This product is a hypertonic, preservative-free, sterile ophthalmic solution, indicated for the temporary relief of the symptoms of corneal edema, such as altered vision and pain. The main ingredients are sodium hyaluronate 0.4% and sorbitol (hypertonic agent).

Materials and methods

The study was conducted on a sample of 22 patients affected by cataract who underwent phacoemulsification using the femto-laser followed by monofocal and multifocal intraocular lens (IOL) implantation.

The sample was divided into 2 groups of 11 patients each: postoperatively, group 1 was treated with the new product Ededay (hypertonic eye drops containing hyaluronic acid 0.4% + sorbitol 13.5%) for the management of postoperative corneal edema, in addition to the routine eye drop protocol consisting of a fixed-dose antibiotic-corticosteroid combination, an anti-inflammatory, and artificial tears; group 2 received the routine treatment protocol, without the hypertonic eye drops. The patients were evaluated at the same timepoints and with the same methods. The eye drops were used to act both on the main and secondary surgical cut, as well as at corneal level for the possible stromal edema caused by the phacoemulsifier.

Two fundamental parameters were assessed: visual acuity and the results of the ophthalmological examination with anterior

segment evaluation. Three postoperative visits were scheduled: the first on day 1-2 after the surgical procedure, the second on day 6 and the third on day 10-12.

Patients in group 1 were instructed to use the hypertonic eye drops starting from the first medication and at a dose of 1 drop 3 times daily, in combination with the routine topical therapy prescribed after cataract surgery. The eye drops were provided to all patients by our centre.

All patients underwent a complete ophthalmological assessment a few days before surgery and at the three scheduled timepoints (day 1-2, 6 and 10-12); each assessment included measurement of natural and/or corrected visual acuity by means of the Snellen chart, determination of intraocular pressure by puff tonometry, and a complete slit-lamp examination of the anterior segment.

All patients were particularly motivated and attended all the scheduled visits without exception, which allowed for a precise and standardized evaluation for both group 1 and group 2.

Results

All the 22 patients in group 1 and group 2 were successfully operated. There were no cases of endophthalmitis or posterior capsule rupture, nor any intraoperative complications.

Patients in group 1 started using Ededay hypertonic eye drops on day 1 or day 2 at the prescribed dose, in combination with the

routine topical products prescribed for all the patients.

Visual acuity

Table 1 shows the results of the visual acuity evaluation after surgery in group 1 (patients who used Ededay, n=11) and group 2 (control group, n=11).

TABLE 1. Visual acuity evaluation (Snellen chart) over a period of 10-12 days after cataract surgery, in group 1 (patients who used Ededay, n=11) versus group 2 (control group, n=11). Each dot represents a patient. The use of Ededay, hypertonic eye drop solution, allowed an early qualitative and quantitative improvement of visual acuity in the patients in group 1, compared to the patients in the control group, who had a slower visual recovery. The patients who used Ededay showed an earlier visual acuity improvement compared to the other group.

Visual acuity	1 st visit (day 1-2 after surgery)		2 nd visit (day 6 after surgery)		3 rd visit (day 10-12 after surgery)	
	Group 1 Ededay	Group 2 Control	Group 1 Ededay	Group 2 Control	Group 1 Ededay	Group 2 Control
10/10					• • • • •	
9/10			•		• • • • •	
8/10			• • • • •			• •
7/10	• •		• • • • •	•		• • • • • •
6/10	•		•	• • • • •		• • •
5/10	• • • • •	• •		• • • • • •		•
4/10	• • •	• • • • • •		•		
3/10		• • •				
2/10		•			•	
1/10			•			
<1/10	•					

All 22 patients had a postoperative natural visual acuity on day 1-2 ranging between 3/10 and 6/10, with the exception of one patient who underwent IOL explantation and concomitant reimplantation in the anterior chamber, whose acuity was less than 1/10.

At the second follow-up visit on day 6, patients in group 1 showed a slight improvement in visual acuity. Patients in group 2 also had an improvement in visual acuity.

At the third visit on day 10-12, patients in

group 1 showed a major recovery of visual acuity. Patients in group 2 showed an improved, though not yet optimal, visual acuity.

It should be noted that the patients in group 2 achieved an improvement in visual acuity 15-20 days after surgery and only after continuing corticosteroid and anti-inflammatory therapy. Patients in group 1, even after discontinuing the hypertonic eye drops, maintained the improvements in visual acuity also beyond the third follow-up visit.

Ophthalmological examination

Table 2 shows the results of the objective evaluation of the anterior segment after surgery in group 1 (patients who used EdeDay, n=11) and group 2 (control group, n=11).

Postoperative tonometry was always normal in both study groups. In some patients, ophthalmological assessment revealed corneal opacification with mild corneal edema, probably due to the phacoemulsification or phacoultrasound, and a corneal edema at the level of the surgical cut, where the hydrosuture was performed at the end of the surgery. At the second follow-up visit on day 6, patients in group 1 showed remission of cor-

neal edema and epitheliopathy, except for the patient who had a major corneal decompensation due to IOL explantation. In patients in group 2 there was still slight corneal opacification and persisting peripheral edema at the level of the surgical cut.

At the third visit on day 10-12, patients in group 1 showed an improvement of the ocular signs and symptoms, a significant reduction of epitheliopathy and edema, and improved corneal transparency in almost all cases, even at the level of the surgical cut. Only the patient with corneal decompensation maintained an edematous cornea and a low visual acuity equal to 2/10. Patients

TABLE 2. Objective data related to edema evaluated over a period of 10-12 days after cataract surgery, group 1 (patients who used EdeDay, n=11) versus group 2 (control group, n=11). Each dot represents a patient. At the third follow-up visit, patients in group 1 showed a major improvement of ocular signs and symptoms, a significant reduction of epitheliopathy and edema and improved transparency of the cornea in almost all cases, even at the surgical cut level. The control group had persistence of peripheral edema or a mild central epitheliopathy that were slower to improve. All the patients with surgical edema in group 1 had an earlier improvement compared to group 2.

Evaluation of the anterior segment	1 st visit (day 1-2 after surgery)		2 nd visit (day 6 after surgery)		3 rd visit (day 10-12 after surgery)	
	Group 1 EdeDay	Group 2 Control	Group 1 EdeDay	Group 2 Control	Group 1 EdeDay	Group 2 Control
Decompensation	•					
Severe		•••••	•		•	
Moderate	•••••	•••••		•••••	•	
Mild	•••	••	•••••	•••••		•••••
Absent					•••••	••

in group 2 showed an improvement in ocular signs and symptoms, but persistence of

mild peripheral edema and mild epitheliopathy in 4-5 cases.

Conclusions

Ededay, hypertonic eye drop solution, was used on a cohort of patients who underwent cataract surgery between November-December 2019 and January 2020 using femtolasar with multifocal or monofocal IOL implantation.

The patients who used Ededay in the postoperative period showed a good response; moreover, they also benefited almost immediately after instillation of the eye drops, in terms of both visual recovery (natural and corrected vision) and resolution of the postoperative corneal edema and epitheliopathy. Ededay was well tolerated by the patients, who reported no discomfort during instillation and showed excellent compliance with this treatment.

From an ophthalmological viewpoint, Ededay eye drops accelerated postoperative recovery,

with a reduction in corneal edema and an improvement in visual function that was evident from day 6 up to day 10-12 (second and third follow-up visits, respectively); these benefits persisted in the following days despite discontinuation of Ededay treatment.

In the group of patients who did not use Ededay, visual recovery was slower (with lower natural and/or corrected vision), with persistence of peripheral edema or mild central epitheliopathy that took longer to improve. Visual acuity improved further after 2 weeks, reaching an optimal level after 20 days of standard topical treatment. In summary, the use of Ededay, hypertonic eye drop solution, seems to allow an early qualitative and quantitative improvement of visual acuity and a reduction of central and peripheral postoperative corneal edema.

References

1. Levenson JE. Corneal edema: Cause and treatment. *Surv Ophthalmol.* 1975;20(3):190–204.
2. Vanmeter WS, Lee WB, Katz DG. Corneal edema. In: Tasman W, Jaeger EA (eds). *Duane's Clinical Ophthalmology.* Vol. 4, Ch. 16A. Philadelphia, PA: Lippincott Williams & Wilkins, 2013.
3. Rosado-Adames N, Afshari NA. The changing fate of the corneal endothelium in cataract surgery. *Curr Opin Ophthalmol.* 2012;23(1):3–6.
4. Claesson M, Armitage WJ, Stenevi U. Corneal oedema after cataract surgery: predisposing factors and corneal graft outcome. *Acta Ophthalmol.* 2009;87(2):154–9.

