

Scientific and Clinical Support for the Use of Dehydrated Amniotic Membrane in Wound Management

Donald E. Fetterolf, MD¹; and Robert J. Snyder, DPM, MSc²

WOUNDS 2012;24(10):299–307

From the ¹MiMedx Group, Inc, Kennesaw, GA; ²Barry University, Miami Shores, FL

Address correspondence to:

Donald E. Fetterolf, MD

MiMedx Group, Inc

60 Chastain Center Blvd, Suite 60

Kennesaw, GA 30144

dfetterolf@mimedx.com

Abstract: Amniotic membrane has been employed in the treatment of wounds for almost 100 years, beginning with early application of natural amniotic membrane obtained from labor and delivery to various types of burns and wounds. Amniotic membrane is rich in collagen and various growth factors that support the healing process to both improve wound closure and reduce scar formation. Unique properties of the material include the lack of immunologic markers, conferring an “immune privileged” status on the allografts; antibacterial properties; and the ability to reduce pain on application. The resurgence of interest in the use of amniotic membrane in a number of applications, including wound treatment, has occurred following improved techniques for preserving the natural membrane. Recently, techniques have been developed to dehydrate the material while preserving many of these wound-healing attributes, to produce a temperature-stable allograft. Future research will continue to yield more information on the unique properties of the amniotic membrane allografts.

Historically, natural amniotic membranes have been successfully used for wound and reconstructive purposes since the early 20th century. John¹ reviewed the subsequent uses of human amniotic membrane over the 20th century to include a number of other applications during that period. These included reconstructive OB/GYN surgery, dentistry, and neurosurgical and general surgical applications.

Davis² reported a comprehensive review of some 550 cases of skin transplantation at the Johns Hopkins University in 1910. Sabella³ and Stern⁴ separately reported on the use of preserved amniotic membranes in skin grafting for burns and ulcers in 1913, although they were familiar with each other's work and collaborated. Amniotic membrane allografts as a wound allograft material have a number of beneficial properties inherent in their makeup. The material provides a natural scaffold for wound healing and contains various important growth factors and biological macromolecules important in wound healing. These molecules have been scientifically found to confer properties that reduce wound pain, suppress infection, suppress scar formation, and provide anti-inflammatory mediators.^{1,7-10}

KEYPOINTS

- Amniotic membrane allografts as a wound allograft material have a number of beneficial properties inherent in their makeup. The material provides a natural scaffold for wound healing and contains various important growth factors and biological macromolecules important in wound healing.
- In 2006, scientists developed methods for cleaning, preparing, and dehydrating human amniotic membranes for surgical use, creating dehydrated sheets of the material that could be cut into sections and stored. Application of this material has been extended to include wounds of other areas, including diabetic neurovascular ulcers, venous stasis ulcers, postoperative or posttraumatic chronic wounds, and postsurgical wound dehiscence.

De Roth⁵ first used amniotic membrane to repair eye wounds in 1940 after noting other materials used for skin grafting in the eye did not appear to have the inherent healing properties of amniotic membranes. Ophthalmologic use would go on to be one of the most popular applications of the material in the late 20th century.

Now numbering more than 45,000 applications by the ophthalmology community, amniotic membrane has been used for conjunctival reconstruction, burn treatment, pterygium repair, and a number of other similar applications, including use in children.⁶

In the latter half of the 20th century, natural amniotic membrane began to be used as a wound covering, beginning in the 1960s through the end of the century, with treatment for diabetic neurovascular ulcers, venous stasis ulcers, and various types of postsurgical and posttraumatic wound dehiscence.^{1,7-11} In these applications, sections of the entire membrane, used in sheet form, were placed on the wound.

However, while the use of amniotic membrane was evidently valuable for the purposes contemplated by the surgeons, it was a somewhat difficult material to incorporate into routine use. While various methods were used to describe how the material might be prepared and preserved,⁵⁶⁻⁵⁹ the tissue remained relatively difficult to reliably source, process, and handle, for obvious reasons. Transportation and storage similarly were difficult, and the material had limited widespread application.

In 2006, scientists developed methods for cleaning, preparing, and dehydrating human amniotic membranes for surgical use, creating dehydrated sheets of the material that could be cut into sections and stored. In this form, the material was easy to handle, stable at room tempera-

ture, and held a shelf-life of up to 5 years, as confirmed via a number of standardized tests. The ophthalmology community quickly adopted the use of this material in eye surgery, where there is now an extensive peer review of the literature, numbering dozens of articles on the subject.¹

Over the past 5 years, application of this material has been extended to include wounds of other areas, including diabetic neurovascular ulcers, venous stasis ulcers, postoperative or posttraumatic chronic wounds, and postsurgical wound dehiscence. Now also numbering in the tens of thousands of applications, dehydrated amniotic membrane has been extended to other potential uses as a reparative membrane in orthopedics, neurosurgery, periodontology, OB/GYN, general and reconstructive surgery, and a number of other medical fields.¹²⁻¹⁷

Amniotic membrane structure and function.

Human amniotic membrane forms the lining of the fetal environment during gestation, separating the developing fetus from the mother *in utero*. The material used for surgical wound allografts is isolated from the membranous sac surrounding the infant to the point where it adjoins the placenta at the chorionic plate. On gross examination, the amniotic membrane is composed of a number of layers that can be seen and appreciated with simple handling and the naked eye. The material easily splits into an amnion layer and chorion layer, separated by a jelly-like, intermediate layer, apparent on separation of the 2 layers. The amnion or fetal side of the membrane is further coated with a layer of epithelial cells, which can be gently removed with simple cell scraping techniques to reveal a translucent underlying membrane. The amnion and chorion layers are in turn each composed of a basement membrane and stromal layer as outlined in Figure 1.

On microscopic examination, the overlying epithelial cells are clearly apparent, while the underlying architecture is defined by the various layers visible in an H/E stain (Figure 2).¹⁸ Overall, the amniotic membrane is composed principally of 3 types of material: structural collagen and extracellular matrix, biologically active cells, and a large number of important regenerative molecules.¹⁹

Extracellular matrix materials form the structural components of the architecture of the membrane and contain a variety of specialized proteins including fibronectin, proteoglycans, glycosaminoglycans, laminins, and other similar materials. Collagens type IV, V, and VII create an important substrate, which is not only important for the structural integrity of the membrane, but also to create advanced wound healing and ingrowth cells. There is clear evidence that many of these molecules interact with one

Layer	Composition
Fetal Side of Membrane	
Epithelial layer	Epithelial cells
Amnion layer	Basement membrane
	Stromal layer
Intermediate layer	Intermediate layer
Chorion layer	Basement membrane
	Stromal layer
Maternal Side of Membrane	

Figure 1. Layers of the amniotic membrane. Used as a wound allograft, the entire membrane is used, placed with the chorion side down against the wound and the epithelial surface upright.

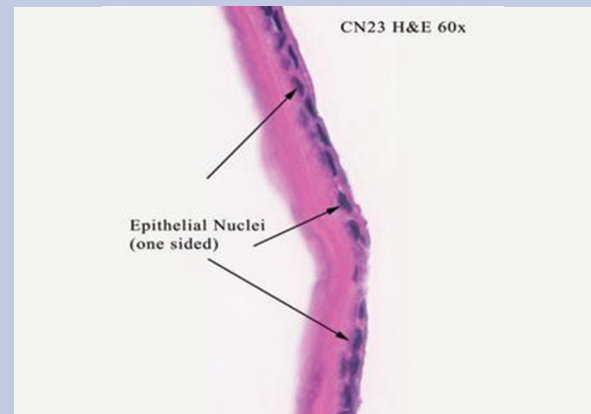


Figure 2. H/E Stain of human amniotic membrane tissue. Note the epithelial cell later visible through the presence of the epithelial cells and their nuclei. Amnion and chorion layers are characterized by a layered appearance.¹⁸

KEYPOINTS

- Extracellular matrix materials form the structural components of the architecture of the membrane and contain a variety of specialized proteins including fibronectin, proteoglycans, glycosaminoglycans, laminins, and other similar materials. Collagens type IV, V, and VII create an important substrate, which is not only important for the structural integrity of the membrane, but also to create advanced wound healing and ingrowth cells.
- The amniotic membrane is also home to a variety of unique molecules with specific functions. Defensins, for example, are a group of molecules that assist in conferring antibacterial properties to the material and are known to increase near the time of delivery. Similarly, both matrix metalloproteinases, which are significant in the role of membrane development, are balanced by tissue inhibitors of metalloproteinases, which confer on the material the ability to both heal and control tissue breakdown.²³

another in a highly complex milieu of bio-regulation that requires the presence of membranes, individual growth factors, and interactions that up-regulate and down-regulate the various regenerative processes of healing. Metalloproteinases for example, are counterbalanced by the tissue inhibitors of these molecules (TIMPS); growth factors, such as fibroblast growth factor, may need the presence of the extracellular matrix components for some functions, and so forth.²⁰

Cellular material includes the epithelial lining of the amnion facing the infant, but also pluripotential stem cells important in regenerating new cellular materials within the membrane lining. Epithelial stem cells, in particular, have also been isolated from the epithelial layer of the amniotic membranes. Fibroblasts are also present and provide lining and strengthening of tissues. The epithelial cells are also biologically active in the healing process through various receptors on the cell surface. The role of hematogenous, mesenchymal, and closely located stem cells is also affected by the interactions among various components of the membrane.

Finally, regenerative biomolecules important in the healing and growth process are concentrated in the amniotic membrane. These include epidermal growth factor, transforming growth factor (TGF) beta, fibroblast growth factors, platelet-derived growth factors, metalloprotein-

ases, and TIMPS. Interestingly, there is a lack of HLA-A, -B, and -C antigens, and beta 2-microglobulin. This, combined with the presence of immunosuppressive cytokines interleukin-4, interleukin-10, and TGF, results in a relatively “immunologically privileged” material that does not present itself as foreign material to either the mother or the infant, and which is likely responsible for its observed lack of rejection in patients treated externally with amniotic membrane.^{21,22}

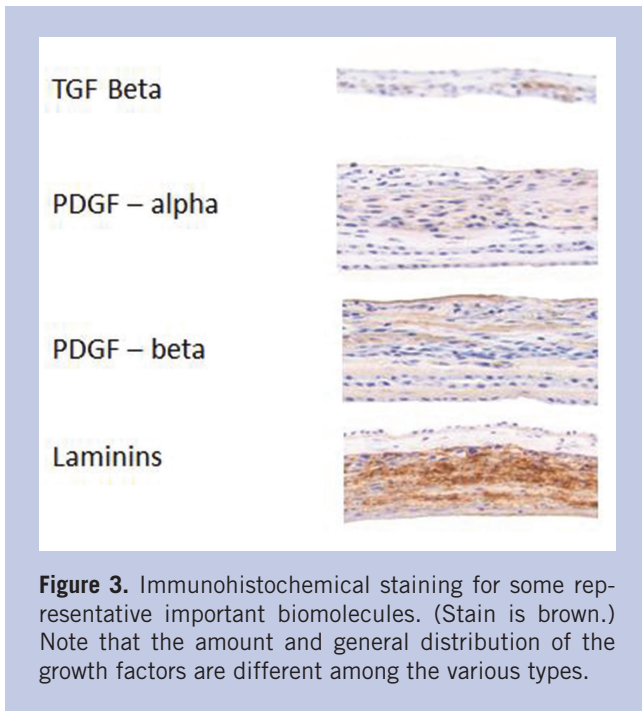


Figure 3. Immunohistochemical staining for some representative important biomolecules. (Stain is brown.) Note that the amount and general distribution of the growth factors are different among the various types.

The amniotic membrane is also home to a variety of unique molecules with specific functions. Defensins, for example, are a group of molecules that assist in conferring antibacterial properties to the material and are known to increase near the time of delivery. Similarly, both matrix metalloproteinases, which are significant in the role of membrane development, are balanced by TIMPS, which simultaneously confer on the material the ability to both heal and control tissue breakdown.²³

Stains of the amniotic membrane in both natural and dehydrated human amniotic membrane (dHAM) clearly show the presence of these various growth factors and cytokines, which have been well-documented in the literature. Similarly, a large number of cytokines have actually been measured in both natural human amniotic membrane and dHAM in various concentrations, presumably accounting for their biological properties.^{24,61,62} The presence of these molecules can be confirmed through immunohistochemical staining, which shows various amounts of the materials at different levels in the membrane (See Figure 3).

Dehydrated human amniotic membrane (dHAM) wound healing properties. Based on the aforementioned anatomic and biochemical properties, human amniotic membrane, as a wound allograft material, has been found to have a number of characteristics that make it uniquely suited to wound healing, and to act as a skin

substitute in various wound applications. These include the observations that amniotic membrane:

- provides a matrix for cellular migration and proliferation;⁷
- promotes increased healing and enhancement of the wound healing process;²⁵
- is non-immunogenic;²¹
- reduces inflammation;²⁶
- reduces scar tissue;²⁷
- has antibacterial properties;^{28,29}
- reduces pain at the site of application;^{12,30-32}
- provides a natural biological barrier;^{12,30,32,33} and
- contains a number of essential growth factors and cytokines, as described above.

Overall, the material has potential uses in a variety of other wound healing applications in addition to cutaneous wounds. The material appears to be safe in its overall use, and contributes significantly to the regeneration of various tissues.^{34,35}

Similarly, the use of amniotic membrane transplantation in the treatment of lower extremity venous ulcers has been addressed in the literature by a number of individuals including Bergan et al,³⁷ Grey et al,³⁶ and others.^{30,38}

A copious amount of literature also exists on the use of amniotic membrane in the treatment of burns, where it has been found to be an effective burn skin substitute material.³⁹⁻⁴³

Biological wound treatments seek to provide many of the important functional characteristics naturally present in amniotic membrane outlined above, including providing a matrix scaffold, biologically active cells for healing and signaling (including stem cells, macrophages, fibroblasts and/or epithelial cells), and important molecular elements including growth factors, cytokines, signaling molecules, defensins, and others. These functions promote healing; reduce inflammation, scar formation, and infection; and have a variety of other actions.

Manufacture and preparation of amniotic tissue in dehydrated form for commercial use. For most of the literature in the first half of the 20th century where amniotic membranes were used, no practical methods of preparation, sterilization, and long-term storage were available.¹ In 1965, Diño et al⁵⁵ noted that amniotic membrane from deliveries could be sterilized and kept for 6 weeks at 4°C and used safely on acute second-degree burns and on skin donor sites.¹² Ganatra et al⁴⁴ described washing the placenta first with saline, then with saline-containing penicillin, prior to applying the material suc-

cessfully to patients with burns. It has also been documented that radiation sterilization has proven to be an effective way to properly prepare the material.⁴²

Advanced tissue stabilization and preservation techniques have caused a resurgence in the use of this material in the treatment of chronic or nonhealing dermal wounds. The PurionSM process (MiMedx Group, Inc, Kennesaw, GA) has created a stable, easily stored, and easily transported material that is becoming an increasingly common application in the treatment of various types of wounds. This approach uses a combination of procedures designed to select low-risk patients, cleanse the membrane of bioburden, gently dehydrate the material, and sterilize the prepared product. Initially marketed to the ophthalmology community, human amniotic membrane allografts made using this process have been successfully used more than 45,000 times in the treatment of eye injuries, burns, and for reparative eye work such as correction of pterygium. More recently, the success of this material as an allograft has been extended to the general treatment of cutaneous wounds.

Amniotic membrane allograft application. For application of amniotic membrane in wound patients, standard medical history and physical examination assessment are still required. Wound cause, duration, presence of comorbidity, and prior treatments are all collected as part of the standard recommended medical history. Typically, advanced biologic allografts are not applied unless a period of conservative therapy has first been tried. Physical examination recommendations include documentation of wound appearance, size (ie, length, width, depth), and the presence of infection or bone exposure. Other standard examination elements include circulatory evaluation for both macro- and micro-circulatory compromise, and neuropathy. Proper wound staging with the Wagner Ulcer Classification grading score is standard practice in wound clinics. Additional other studies are necessary, including laboratory tests such as complete blood count, sedimentation rate and glucose, as well as tests for microvascular supply.

Surgical wound bed preparation is first completed to ensure the wound is free from clinical signs of infection or decaying tissue, including sharp debridement of the wound to a visible wound base with good blood flow. Next, graft orientation of the amniotic membrane is determined with the stromal collagen layer facing the wound. In the case of EpiFix (MiMedx Group, Inc, Kennesaw, GA), this is achieved through confirmation that the embossment “SB” (ie, Surgical Biologics, the MiMedx subsidiary

that produces the material) on the surface of the graft is visible and the implanted material is placed correct-side up. Graft preparation is fairly straightforward. The material is supplied in a sterile container and sterile dry scissors are used to cut the material to fit the wound margin. It is acceptable to overlap the wound margin with the material by 1 mm. The material can be applied wet or dry and may be more easily manipulated if moistened with wet saline prior to application. Amniotic membrane wound allografts do not need to be sutured, and can be held in place with only “steri-strip” type adhesive attachments. The graft should be covered with a non-adherent contact layer (eg, Adaptic [Johnson and Johnson, New Brunswick, NJ] or Mepitel [Mölnlycke Health Care, Gothenburg, Sweden]) and should not be disturbed, if possible, for at least 1 week to 2 weeks. The secondary dressing environment should be moist, and appropriate moisture management dressing for the wound type and treatment is recommended. Various support therapies can be used as needed. Dehydrated human amniotic membrane is compatible with offloading, decompression, and negative pressure therapies, and may be used in conjunction with hyperbaric oxygen therapy. Collagenase-based pastes or creams should not be used, since the enzymes would potentially destroy much of the valuable underlying cellular architecture of the material.

KEYPOINTS

- Surgical wound bed preparation is first completed to ensure the wound is free from clinical signs of infection or decaying tissue, including sharp debridement of the wound to a visible wound base with good blood flow. Next, graft orientation of the amniotic membrane is determined with the stromal collagen layer facing the wound.
- General experience is that the amniotic membrane allograft will incorporate into the wound bed within 1 week to 2 weeks. The medical practitioner should anticipate seeing some improvement in the wound margins and depth within 2 weeks to 3 weeks.

General experience is that the amniotic membrane allograft will incorporate into the wound bed within 1 week to 2 weeks. The medical practitioner should anticipate seeing some improvement in the wound margins and depth within 2 weeks to 3 weeks. Anecdotally, wound margins can typically reduce by 40% - 50% within 3 weeks to 4 weeks in typical wounds, compared to more than 4 weeks of standard therapy. A second graft may be

Percent Area Reduction (PAR) Tool

Patient's Name: _____ Date: _____ Wound Number: _____

Percent Area Reduction				
Week 0	Week 1	Week 2	Week 3	Week 4
Wound Baseline ____cm ²	> 25% ----- < 25%	> 30% ----- < 25%* < 40%	> 40% ----- < 25%* < 40%	> 50% ----- < 50%*
Calculation	_____%	_____%	_____%	_____%
	Smaller Unchanged Larger	Smaller Unchanged Larger*	Smaller Unchanged* Larger*	Smaller Unchanged* Larger*
*Consider advanced therapies ⁴⁹				

Figure 4. Snyder-Fetterolf 4-Week Percent Area Reduction (PAR) Tool. Review of wound size at weekly intervals can develop an early predictive model for a decision to utilize advanced biologic treatments. (Area reduction is calculated by subtracting the wound area at the week in question from the area at Week 0 and dividing by the Week 0 value.) Ulcers with slow wound healing kinetics and/or reduced improvement at 4 weeks will benefit from advanced biologic treatments such as amniotic membrane allografts.

applied when slowing of the wound margin reduction is observed in measurements over time. Chronic wounds can remain problematic however, and must still be closely followed.⁴⁵

Snyder-Fetterolf 4-Week PAR Tool. Margolis et al⁴⁶ performed a meta-analysis on individuals with diabetes with neuropathic ulcers to ascertain effectiveness of standard care with moist wound healing and appropriate clinical practice guidelines (CPG), at 12 weeks and 20 weeks, respectively. The analysis gleaned abysmal results with a 24.1% (n = 425) and 31.2% (n =175) healing rate at 12 weeks, respectively. This research, however, created catalysts for change, including the need for pivotal clinical decision points that could foster practitioner introspection and reevaluation of reasons for delayed healing and the potential need for advance therapies.

In a retrospective analysis of 203 patients, Sheehan et al⁴⁷ concluded that if a wound failed to resurface by at least 50% (percent area reduction [PAR]) in the first 4 weeks of therapy, the wound was unlikely to completely epithelialize in 12 weeks, thus representing a negative predictor of healing. Snyder et al⁴⁸ conducted a retrospec-

tive analysis of 2 randomized controlled studies (n = 133 and n =117, respectively) and found only 5% and 2%, respectively, healed in 12 weeks if the PAR was less than 50%, thus validating Sheehan's hypothesis. It remains clear that advanced therapies such as dHAM could be useful in facilitating a PAR of > 50% at 4 weeks, accelerating healing.

Based upon the literature, the aforementioned tool may be helpful in establishing when a cutting edge therapy such as dHAM may be useful. The key to effective

KEYPOINTS

- Based upon the literature, the Snyder-Fetterolf 4-Week PAR Tool may be helpful in establishing when a cutting edge therapy such as dehydrated human amniotic membrane (dHAM) may be useful. The key to effective treatment is to use advanced therapies early in the treatment paradigm.
- Human amniotic membrane allografts present an effective, value-based solution for wound care in clinics and hospitals across a number of domains.

treatment is to use advanced therapies early in the treatment paradigm.

Cost effectiveness. Untreated or chronic non-healing wounds represent a significant cost to both patients and society. Nonhealing leg ulcers have a high predictive value for forward future medical costs, and are a health informatics marker for increased health care costs in the population of individuals with this pathology. Patients with chronic nonhealing wounds can have medical care costs that have been quoted as high as \$30,000 to \$40,000 per year.⁴

Data from a retrospective analysis of 974 home care patients performed by Snyder et al,⁵⁰ suggests that treatment with saline-gauze dressings applied daily may be 10 times more costly than advanced therapies and provide fewer benefits. Furthermore, retrospective data collected by Lazaro-Martinez et al,⁵¹ involving 40 patients, revealed that treating neuropathic ulcers in patients with diabetes utilizing an advanced product, such as collagen/oxidized regenerated cellulose, could provide an excellent cost-benefit ratio that saves an average of \$2,280.13/patient over 6 weeks of treatment. Additionally, a review of the literature supports the hypothesis that improved and faster healing of neuropathic ulcers in patients with diabetes may reduce the incidence of amputation;⁵² amputations are associated with increased direct cost of care ranging from \$22,000 to \$60,000.⁵³

Despite this evidence, clinicians often avoid advanced therapies in favor of saline-gauze (wet-to-dry), foams, or generic moist wound healing products, because they are still perceived as having little benefit and being too expensive when compared to traditional methods. Although it is true that modern products have a higher unit cost, they require fewer dressing changes, making them more cost effective.⁶⁰ If other issues such as time to healing, clinician confidence that the appropriate therapy is being utilized, and quality of life are included, cost effectiveness should be a major force for change.⁵⁴

Proper and definitive treatment of chronic wounds is an important clinical goal for health plans, hospitals, and medical practices, but particularly for patients with significant, exacerbating, underlying comorbidities, or who must bear the significant cost that treatment of this condition entails. Human amniotic membrane allografts present an effective, value-based solution for wound care in clinics and hospitals across a number of domains.

Conclusion

Human amniotic membrane is a uniquely suited mate-

rial for use as an allograft in wound management. Used in its natural form, then later in preserved preparations, the material assists in the healing process through a number of physical, biochemical and molecular biological pathways to promote regenerative healing while simultaneously reducing scar formation. Dramatic wound closure rates have been demonstrated for chronic wounds, while evolving characterization of the mechanisms involved indicate deep involvement of the molecular biology of the healing process that is occurring. Wounds respond best to advanced therapies, such as dHAM, when utilized early in the treatment regime; the PAR Tool elucidated in this manuscript may help make appropriate decisions in this regard. Additional research and characterization of this process will more completely define the dramatic results seen in the application of this material.

Disclosure

Dr. Fetterolf is Chief Medical Officer of MiMedx Group, Inc, manufacturer of EpiFix dehydrated amniotic membrane; Dr. Snyder is Consultant to MiMedx Group, Inc.

References

1. John, T. Human amniotic membrane transplantation: past, present, and future. *Ophthalmol Clin North Am.* 2003;16(1):43-65.
2. Davis JW. Skin transplantation with a review of 550 cases at the Johns Hopkins Hospital. *Johns Hopkins Med J.* 1910;15:307-396.
3. Sabella N. Use of fetal membranes in skin grafting. *Med Records NY.* 1913;83:478-480.
4. Stern M. The grafting of preserved amniotic membrane to burned and ulcerated surfaces, substituting skin grafts. *JAMA.* 1913;60(13):973-974.
5. De Roth A. Plastic repair of conjunctival defects with fetal membranes. *Arch Ophthalmol.* 1940;23(3):522-525.
6. Internal records, Surgical Biologics, Inc, Kennesaw, GA. Accessed August 23, 2012.
7. Cornwell KG, Landsman A, James KS. Extracellular matrix biomaterials for soft tissue repair. *Clin Podiatr Med Surg.* 2009;26(4):507-523.
8. Bose B. Burn wound dressing with human amniotic membrane. *Ann R Coll Surg Engl.* 1979;61(6):444-447.
9. Quinby WC, Hoover HC, Scheffan M, et al. Clinical trials of amniotic membranes in burn wound care. *Plast Reconstr Surg.* 1982;70:711-716.
10. Sawhney CP. Amniotic membrane as a biological dressing in the management of burns. *Burns.* 1989;15(5):339-342.
11. Pigeon J. Treatment of second-degree burns with amniotic

- membranes. *Can Med Assoc J*. 1960;83:844-845.
12. Ganatra MA. Amniotic Membrane in Surgery. *J Pak Med Assoc*. 2003;53(1):29-32.
 13. Koziak A, Salagierski M, Marcheluk A, Szczesniewski R, Sosnowski M. Early experience in reconstruction of long ureteral strictures with allogenic amniotic membrane. *Int J Urol*. 2007;14(7):607-610.
 14. Tao H, Fan H. Implantation of amniotic membrane to reduce postlaminectomy epidural adhesions. *Eur Spine J*. 2009;18(8):1202-1212.
 15. Chou CT, Lee C, Hwang JL. Amniotic membrane used for vulvar adhesion treatment. *Arch Gynecol Obstet*. 2001;265(4):223-224.
 16. Fotopoulou C, Sehoul J, Gehrman N, Schoenborn I, Lichtenegger. Functional and anatomic results of amnion vaginoplasty in young women with Mayer-Rokitansky-Küster-Hauser syndrome. *Fertil Steril*. 2010;94(1):317-323.
 17. Demirkan F, Colakoglu N, Herek O, Erkula G. The use of amniotic membrane in flexor tendon repair: an experimental model. *Arch Orthop Trauma Surg*. 2002;122(7):396-399.
 18. Premier Laboratories, LLC. Longmont, CO. Immunohistochemical staining to determine the presence or absence of collagen IV, V, and VII, Laminin, TGF-beta, EGF, FGF, PDGF-alpha, and PDGF-beta in non-processed human amniotic membrane as opposed to processed amniotic membrane samples. Study Numbers: 2011-261, 2011-432. Study completed 2011.
 19. Schmidt W. The amniotic fluid compartment: the fetal habitat. *Adv Anat Embryol Cell Biol*. 1992;127:1-100.
 20. Schultz GS, Davidson JM, Kirsner RS, Bornstein P, Herman IM. Dynamic reciprocity in the wound microenvironment. *Wound Repair Regen*. 2011;19(2):134-148.
 21. Akle C, Adinolfi M, Welsh KI, Leibowitz S, McColl I. Immunogenicity of human amniotic epithelial cells after transplantation into volunteers. *Lancet*. 1981;2(8254):1003-1005.
 22. Park CY, Kohanim S, Zhu L, Gehlbach PL, Chuck RS. Immunosuppressive property of dried human amniotic membrane. *Ophthalmic Res*. 2008;41(2):112-3.
 23. Fortunato SJ, Menon R, Lombardi SJ. Presence of four tissue inhibitors of matrix metalloproteinases (TIMP-1, -2, -3 and -4) in human fetal membranes. *Am J Reprod Immunol*. 1998;40(6):395-400.
 24. Paradowska E, Blach-Olszewska Z, Gejdel E. Constitutive and induced cytokine production by human placenta and amniotic membrane at term. *Placenta*. 1997;18(5-6):441-446.
 25. Kim JS, Kim JC, Na BK, Jeong JM, Song CY. Amniotic membrane patching promotes healing and inhibits proteinase activity on wound healing following acute corneal alkali burn. *Exp Eye Res*. 2000;70(3):329-337.
 26. Hao Y, Ma DH, Hwang DG, Kim WS, Zhang F. Identification of antiangiogenic and antiinflammatory proteins in human amniotic membrane. *Cornea*. 2000;19(3):348-352.
 27. Tseng SC, Li DQ, Ma X. Suppression of transforming growth factor-beta isoforms, TGF-beta receptor type II, and myofibroblast differentiation in cultured human corneal and limbal fibroblasts by amniotic membrane matrix. *J Cell Physiol*. 1999;179(3):325-335.
 28. King AE, Paltoo A, Kelly RW, et al. Expression of natural antimicrobials by human placenta and fetal membranes. *Placenta*. 2007;28(2-3):161-169.
 29. Talmi Y, Sigler L, Inge E, Finkelstein Y, Zohar Y. Antibacterial Properties of Human Amniotic Membranes. *Placenta*. 1991;12(3):285-288.
 30. Mermet I, Pottier N, Sainthillier JM, et al. Use of amniotic membrane transplantation in the treatment of venous leg ulcers. *Wound Repair Regen*. 2007;15(4):459-464.
 31. Adly OA, Moghazy AM, Abbas AH, et al. Assessment of amniotic and polyurethane membrane dressings in the treatment of burns. *Burns*. 2010;36(5):703-710.
 32. Lorusso R, Geraci L, Masellis M. The treatment of superficial burns with biological and synthetic material: frozen amnion and biobrane. *Annals of the MBC*. 1989;2(2):79-84.
 33. Niknejad H, Peirovi H, Jorjani M, et al. Properties of the amniotic membrane for potential use in tissue engineering. *Eur Cell Mater*. 2008;15:88-99.
 34. Chen E, Tofe A. A literature review of the safety and biocompatibility of amnion tissue. *J Impl Adv Clin Dent*. 2010;2(3):67-75.
 35. Toda A, Okabe M, Yoshida T, Nikaido T. The potential of amniotic membrane/amnion-derived cells for regeneration of various tissues. *J Pharmacol Sci*. 2007;105(3):215-228.
 36. Grey JE, Harding KG, Enoch S. Venous and arterial leg ulcers. *BMJ*. 2006;332(7537):347-350.
 37. Bergan JJ, Schmid-Schönbein GW, Coleridge Smith PD, et al. Mechanisms of disease: chronic venous disease. *N Engl J Med*. 2006;(355):488-498.
 38. Pesteil F, Drouet M, Rousanne M, Lacroix P. Amniotic membrane: An innovative treatment of refractory vascular ulcers. *Phlebology*. 2009;16(2):259-265.
 39. Lineen E, Namias N. Biologic dressing in burns. *J Craniofac Surg*. 2008;19(4):923-928.
 40. Sharma SC, Bagree MM, Bhat AL, Banga BB, Singh MP. Amniotic membrane is an effective burn dressing material. *Jpn J Surg*. 1985;15(2):140-143.

41. Kesting MR, Wolff KD, Hohlweg-Majert B, Steinstraesser L. The role of allogenic amniotic membrane in burn treatment. *J Burn Care Res.* 2008;29(6):907-916.
42. Singh R, Purohit S, Chacharkar MP, Bhandari PS, Bath AS. Microbiological safety and clinical efficacy of radiation sterilized amniotic membranes for treatment of second-degree burns. *Burns.* 2007;33(4):505-510.
43. Branski LK, Herndon DN, Celis MM, et al. Amnion in the treatment of pediatric partial-thickness facial burns. *Burns.* 2008;34(3):393-399.
44. Ganatra MA, Durrani KM. Method of obtaining and preparation of fresh human amniotic membrane for clinical use. *J Pak Med Assoc.* 1996;46(6):126-128.
45. Warriner RA, Snyder RJ, Cardinal MH. Differentiating diabetic foot ulcers that are unlikely to heal by 12 weeks following achieving 50% percent area reduction at 4 weeks. *Int Wound J.* 2011;8(6):632-637.
46. Margolis D, Kantor J, Berlin J. Healing of neuropathic ulcers receiving standard treatment: a meta-analysis. *Diabetes Care.* 1999;22(5):692-695.
47. Sheehan P, Jones P, Caselli A, Giurini JM, Veves A. Percent change in wound area of diabetic foot ulcers over a 4-week period is a robust predictor of complete healing in a 12 week prospective trial. *Diabetes Care.* 2003;26(6):1879-1882.
48. Snyder R, Cardinal M, Dauphinee DM, Stavosky J. A post-hoc analysis of reduction in diabetic foot ulcer size at 4 weeks as a predictor of healing by 12 weeks. *Ostomy Wound Manage.* 2010;56(3):44-50.
49. Snyder R, Cardinal M, Dauphinee D, Stavosky J. Diabetic foot ulcers: less than 50% closure in 4 weeks predicts failure to heal by 12 weeks. Poster presented at Diabetic Limb Salvage Conference, September 24-26, 2009; Washington, DC.
50. Snyder RJ, Richter D, Hill ME. A retrospective study of sequential therapy with advanced wound care products versus saline gauze dressings: comparing healing and cost. *Ostomy Wound Manage.* 2010;56(11A):9-15.
51. Lazaro-Martinez JL, Aragn-Sanchez FJ, Garcia-Morales E, et al. A retrospective analysis of the cost-effectiveness of collagen/oxidized regenerated cellulose dressing in the treatment of neuropathic diabetic foot ulcers. *Ostomy Wound Manage.* 2010;56(11A):4-8.
52. Steed DL, Attinger C, Colaizzi T, et al. Guidelines for the treatment of diabetic ulcers. *Wound Repair Regen.* 2006;14(6):680-692.
53. Eckman MH, Greenfield S, Mackey WC, et al. Foot infections in diabetic patients: decision and cost effectiveness analysis. *JAMA.* 1995;273(9):712-720.
54. Ovington LG. Hanging wet to dry dressing out to dry. *Home Healthc Nurse.* 2001;19(8):477-483.
55. Diño BR, Eufemio G, De Villa M, Reysio-Cruz M, Jurado RA. The use of fetal membrane homografts in the local management of burns. *J. Philippine Med Assoc.* 1965;41(12) (suppl):890-898.
56. Hermans MH. Preservation methods of allografts and their (lack of) influence on clinical results in partial thickness burns. *Burns.* 2011;37(5):873-881.
57. Riau AK, Beuerman RW, Lim LS, Mehta JS. Preservation, sterilization and de-epithelialization of human amniotic membrane for use in ocular surface reconstruction. *Bio-materials.* 2010; 31(2):216-225.
58. Singh R, Gupta P, Kumar P, Kumar A, Chacharkar MP. Properties of air dried radiation processed amniotic membranes under different storage conditions. *Cell Tissue Bank.* 2003; 4 (2-4):95-100.
59. von Versen-Höynck F, Syring C, Bachman S, Möller DE. The influence of different preservation and sterilisation steps on the histological properties of amnion allografts—light and scanning electron microscopic studies. *Cell Tissue Bank.* 2004;5(1):45-56.
60. Marston WA, Hanft J, Norwood P, Pollack R; and Dermagraft Diabetic Foot Ulcer Study Group. The efficacy and safety of Dermagraft in improving the healing of chronic diabetic foot ulcers: results of a prospective randomized trial. *Diabetes Care.* 2003;26(6):1701-1705.
61. Hao Y, Ma DH, Hwang DG, Kim WS, Zhang F. Identification of antiangiogenic and antiinflammatory proteins in human amniotic membrane. *Cornea.* 2000;(19)3:348-352.
62. Keelan JA, Blumenstein M, Helliwell RJ, Sato TA, Marvin KW, Mitchell MD. Cytokines, prostaglandins and parturition—a review. *Placenta.* 2003; 24 Supplement A: S33-S46.